

Protective Effects of Alfa Lipoic Acid on Amiodarone Induced Hypothyroidism in Adult Male Albino Rats (A Biochemical, Histopathological and Immunohistochemical Study)

Amal Mahmoud Elshazly^{1*}, Bodour Baiomy¹, Yasmeen Mohammed Ismail El Sayed²,
Asmaa Y.A. Hussein^{3*}, Neama Mahmoud Taha⁴, and Ali Mohamed Ali¹.

¹Department of Anatomy and Embryology, ²Department of Clinical Pharmacology,

³Department of Forensic Medicine & Clinical Toxicology, Faculty of Medicine, Benha University, Egypt

⁴Physiology Department, Umm Al-Qura University, KSA.

Corresponding author: Amal Elshazly, **Mobile:**(+20)1222924128, **Email:** amal.elshazly79@yahoo.com

<https://orcid.org/0000-00031051-7241>

ABSTRACT

Background: Amiodarone (AMD) is a highly effective antiarrhythmic agent. Its utilization is associated with toxic effects on thyroid gland. The aim of this research to evaluate the AMD chronic administration potential toxic impact on the thyroid gland and evaluate Alfa lipoic acid (α LA) possible protective impact.

Materials and methods: 40 adult male albino rats were equally separated into 4 groups, group I (control) given 1ml distilled water for 12 wks., group II (AMD tested group) received a single dose of 40 mg/kg /day AMD for 12 wks. Group III (AMD+ α -LA), where AMD was given as group II and a dose of 100 mg/kg of α -LA for 12 weeks, group IV received AMD in doses similar to group II, then the drug was withdrawn and the rats took no treatment for additional 4 weeks. All groups were sacrificed after 12 weeks except group IV after 16 weeks from the beginning of the experiment.

Results: In AMD treated group; the T3, T4 and catalase [CAT] serum levels were significantly reduced along with significant elevation in TSH, IL6 and malondialdehyde [MDA] level, light microscopic examination of AMD group showed cellular degeneration of follicles and colloid peripheral vacuolation along with strong positive immune reaction for Ki-67 declared in AMD group as compared to those of other groups. Additionally, electron microscopic studies supported these results. Conclusion: Chronic administration of AMD induced thyroid damage which could be improved by Co-supplementation of α -LA.

Keywords: Amiodarone, Alfa Lipoic Acid, thyroid gland, hypothyroidism.

INTRODUCTION

Being a benzofuran derivative, amiodarone (AMD) is a class III effective antiarrhythmic agent with non-competitive α - and β adrenergic blocker and multichannel blocker properties. Due to its little negative inotropic impact, it is frequently utilized, even in heart failure cases^(1,2).

The long-term administration of AMD may be accompanied with direct and/or indirect organ toxicities, including hepatotoxicity, thyroid dysfunction, corneal microdeposits and lung toxicity^(3,4). AMD has numerous impacts on physiology of the thyroid and peripheral metabolism of thyroid hormones. In fact, greater than 50% of patients receiving prolonged treatment of AMD have abnormal thyroid function test results. The pathogenesis of AMD is multifactorial, and may be related to its lipophilic nature, presence of 2 iodine atoms, a high propensity for deposition in various tissues, high bio-distribution potential, and long half-life in plasma (13–30 days)⁽⁵⁾.

Several clinical and experimental studies revealed many thyroidal disturbances associated with AMD therapy such as hypothyroidism, thyroiditis, follicular cell hyperplasia & follicular cell tumors. Long term administration of AMD is highly affecting thyroid hormones metabolism and causes direct toxic effect on the thyroid^(6,7).

Varying degrees-of thyroid gland abnormalities were detected in response to AMD treatment related to certain factors in each specific case. Some examples of

these factors include age, sex, the dose and duration of AMD therapy, absence or existence of underlying thyroid disease and the level of body iodine. However, most studies attributed the potential ability of AMD problems to the high iodine content of the drug; as every AMD molecule contains 2 atoms of iodine making it closely similar to the structure of thyroid hormones^(6,8).

An adaptive blockade of additional thyroidal iodide uptake and subsequent production of thyroid hormone, known as the effect Wolff-Chaikoff occurs during AMD therapy, due to the significant amount of iodide liberated from its metabolism. Although the effect is noticeable through the first 2 wks. of treatment, normal thyroid hormone production is restored due to continued exposure to iodine. As a result of failure of thyroid to escape the Wolff-Chaikoff effect, amiodarone-induced hypothyroidism (AIH) is induced. Because of the prolonged blockage of intrathyroidal iodine organification, thyroid hormone production is hindered⁽⁹⁾.

Characteristic destructive thyroiditis associated with AMD chronic administrations occurs due to its direct toxic effect with its iodide content that induced oxidative stress, characterized by generation of reactive oxygen species (ROS) and a significant rise in the levels of lipid peroxide on normal thyroid cells and follicles with subsequent thyroid gland degeneration. Also, AMD was found to be concentrated in the thyroid, and when its concentration exceed certain limit, damage and destruction occurs in thyroid cells. This results in the

release of inflammatory cytokines such as IL6 that evoke inflammatory process⁽¹⁰⁾.

Alpha-lipoic acid (α -LA) is a powerful antioxidant with high reactivity to free radicals that promotes regeneration. It has been shown to be beneficial in preventing pathogenic processes due to its effects of ROS⁽¹¹⁾.

THE AIM OF THE WORK

The current research was performed to assess the role of oxidative stress, incidence of thyroid toxic abnormalities and alteration due to long-term AMD administration and to detect the possible protective role of α -LA as an antioxidant in the alleviation of amiodarone-induced thyroid damage in adult albino rats.

MATERIALS AND METHODS

Experimental animals:

Forty healthy adult male albino rats with 200-220 grams weight obtained from the animal house at the Faculty of Veterinary Medicine, Banha University. According to the laboratory animal's care guidelines, they were housed in plastic cages. The animals were preserved in the animal house under controlled housing environment, Anatomy Department, Faculty of Medicine, Banha University. They were kept at controlled room temperature (22-25°C), with a 12-hour light/dark cycle. The animals were kept for two week and fed a diet of 10% varied vegetables, 20% dry milk, 20% yellow maize, 50% barley, and tap water prior to the experimental investigation.

Chemicals:

1. Cordarone tablets contained 200mg of AMD hydrochloride were provided by Global Nabi for pharmaceutical products under license from Sanofi Synthelabo.
2. Alpha-lipoic acid in form of powder was provided from EVA Pharma (Cairo, Egypt).
3. All utilized reagents and additional chemicals were of highest purity and analytical grades. They were purchased from the Egyptian scientific wholesalers.

Studied chemical parameters:

a. Determination of Triiodothyronine (T3), Thyroxine (T4), thyroid stimulating hormone (TSH):

Enzyme linked immunosorbent assay (ELISA) kits purchased from (MyBioSource, Inc., San Diego, USA, for T3& T4 and BioVendor, Czech Republic) for TSH were used according to the instructions of the manufacturer to evaluate T3, T4 and TSH concentration in the serum samples

b. Determination of Interleukin 6 (IL6):

Enzyme linked immunosorbent assay (ELISA) was used to evaluate IL6. The kits were purchased from an Eagle Biosciences, Inc.

c. Determination of oxidative stress parameters (blood malondialdehyde (MDA) and catalase (CAT):

ELISA kits utilized to evaluate MDA and CAT serum level were purchased from Life Span Biosciences company (LSBio), North America for MDA and Shanghai Blue Gene Biotech CO., LTD for CAT.

Dosage regimen and vehicle:

Each Cordarone tablet (200mg) was grounded in the form of powder, dissolved in 5mL distilled water forming a suspension of 40 mg/1ml of Amiodaron hydrochloride (AMD). It was given orally in a single dose of 40 mg/kg /day^(8,12). While the daily dose of Alpha lipoic acid (α -LA) was 100mg/kg body weight, orally⁽¹³⁾.

Experimental procedure and treatments:

All drugs dissolved in distilled water and used for treatment were freshly prepared, and given to the rats by a stomach tube as a single daily dose for 12 consecutive weeks.

Forty rats were randomly divided into 4 equal groups. Group I (control) received 1ml of distilled water for 12 weeks, group II (AMD tested group) received a single daily dose of 40mg/kg /day of (AMD) for 12weeks. Group III (AMD+ α -LA), received (AMD) the same as group II plus a dose of 100 mg/kg of (α -LA) for 12 weeks. Group IV received (AMD) in a dose similar to group II, then the drug was withdrawn, and the rats took no treatment for additional 4 weeks. All rats were sacrificed after 12 weeks except group IV after 16 weeks from the start of the experiment.

Sampling:

All the rats were slaughtered by cervical dislocation at the end of the experiment after receiving an anesthetic dose of 0.86 mg/kg sodium pentobarbital intraperitoneally. Blood samples were taken from the abdominal aorta and collected in sterile centrifuge tubes to study the biochemical changes. Thyroid specimens were excised and used for immunohistochemical and histopathological studies.

Histopathological study of the thyroid gland:

- **For light microscopic examination**, in 10% neutral formalin buffer solution thyroid specimens were fixed and processed in paraffin wax bars. Then, sliced at 5 μ m thickness sections and were stained with H &E stain⁽¹⁴⁾. Mallory's trichrome stain was used to detect collagen fibers in the thyroid tissue⁽¹⁵⁾.
- **For transmission electron microscopy (TEM) examination**, other thyroid specimens were collected, cut into smaller pieces (1mm³), promptly fixed for 2 h in 2.5% glutaraldehyde in 0.1M phosphate buffer (pH 7.4) at 4 C degrees, and then treated with 1.5% osmium tetroxide as a post-fixative (4 C, 1.5 h). The material was dehydrated

by immersion in ethanol dilutions (50, 70, 90, 95, and 4-times 100 %, each for 15 min) and acetone for 30 min. Finally, epoxy resin (Epoxy Embedding Medium Kit; Sigma) was used to embed the specimens. Ultramicrotome (RMC PT-XL Power Tome Ultramicrotome) was utilized to cut semi- and ultra-thin sections. Using an Olympus BX61 light microscope, semithin (1 μ m) slices stained with 1% toluidine blue were examined. Ultra-thin sections were cut at a thickness of 70-90 nm, stained with 2.5% uranyl acetate as the main stain and as the counter stain lead citrate was utilized, and then processed for examination using a JEM-1400 Plus (JEOL, Japan) TEM at the electron microscope unit, faculty of Science at Banha University, Egypt ⁽¹⁶⁾.

- **For Ki67 immunohistochemical study of the thyroid gland:** The sections were immunostained using avidin-biotin technique. The sections were stained with rabbit anti-Ki-67 antiserum (Sigma-Aldrich, St Louis, USA) ⁽¹⁷⁾.

Histomorphometric studies:

The image analysis software program (Image j. 1.46version) was used to examine sections from the thyroid gland in all groups. The optical density of collagen fiber deposition was measured in 5 randomly different microscopic fields for each specimen at x400 magnification power.

The Ki67-immuno-expression mean area percentage was calculated using 5 images from 5 non-overlapping fields. ⁽¹⁸⁾.

Ethical approval:

The experimental protocol and all procedures were approved by local ethical Committee of Scientific Research, Faculty of Medicine, Benha University, Egypt, (No. RC.5.8.2022).

Statistical analysis:

All the data were collected, tabulated, and analyzed statistically by IBM/PC. SPSS (Statistical Package for the Social Sciences version 20.0; SPSS Inc., Chicago, IL Company) was utilized for the statistical analysis. The data was presented in mean \pm SD. The Shapiro-Wilks test was used to check normality with the assumption that $P > 0.05$ indicates normality. One-way ANOVA for normally distributed variables tested differences between groups, followed by post hoc multiple comparisons using Bonferroni and Games-Howell tests to identify statistically significant pairs. P value of less than 0.05 is regarded to be statistically significant ⁽¹⁹⁾.

RESULTS

Serum biochemical assays:

1. Thyroid hormone levels and Serum interleukins concentrations:

As shown in Table 1, AMD treatment resulted in impairment of thyroid functions, as documented by

marked decreases in the serum indices T3 and T4, as well as marked increases in TSH when compared to the control. By contrast, when AMD treated rats were given α -LA or AMD was withdrawn, the harmful effects of AMD were reduced, as evidenced by a significant improvement in TSH profile and thyroid hormones levels.

In the same table, we also noticed a significant increase in serum interleukin-6 concentrations (IL-6) in AMD treated rats above the control level. These findings revealed that AMD poisoning induced inflammation. While in AMD co administrated α -LA and AMD withdrawal groups. Serum IL-6 was significantly decreased in comparison with AMD; however, this reduction was non-significant when compared with control group.

2. Oxidative stress indices; Malondialdehyde (MDA) & Catalase (CAT):

Lipid peroxidation biomarker (MDA) and antioxidant enzyme capacity (CAT) in studied groups are illustrated in table (1). As observed, AMD exposure induced a significant increase in the MDA levels along with significant depletion in CAT activity level in the blood when compared to the control. However, in (AMD + α -LA) and (AMD withdrawal) groups there was significant improvement in oxidative harm induced by AMD exposure.

Histopathological Results:

1. Light microscopic findings:

a. Hematoxylin and Eosin staining:

thyroid sections of the control group showed normal construction of the thyroid gland in which follicles of almost equal sizes that were lined by simple low cuboidal follicular epithelial cells surrounding the acidophilic homogenous colloid inside its follicular lumen. Interfollicular cells appear normal in shape between the follicles (Figs. 1A&1B).

On the contrary, Amiodaron (AMD) treated group showed loss of normal pattern and degeneration of thyroid gland follicles were noticed. The follicles were irregular in shape with marked epithelial hyperplasia of some follicles lining. They were lined by stratified columnar cells with atypical nuclear changes. These hyperplastic cells obliterated the follicular lumen and the follicles appeared depleted from the colloid. Also, there were hemorrhage inside the acini and vacuolated follicular cells with dark nuclei with some shaded off cells lined other follicles. The stroma between the follicles showed increased amount of fibrous tissue. There were areas of hemorrhage and necrosis in the interstitial tissue, as well as inflammatory cell infiltration (Figs. 3A& 3B).

Fortunately, in (AMD+ α -LA) and (AMD withdrawal) group respectively, there were reverted thyroid architecture mostly to normal with retained normal follicular pattern and structure with normal cuboidal epithelial lining and acidophilic colloid. Few follicles showed some vacuolated follicular cells with

few colloids which appeared heterogeneous and much less inflammatory infiltration (Figs. 4A& 4B).

b. Mallory’s trichrome staining Image:

The thyroid gland of control rats showed little collagen fibers in the connective tissue septa around thyroid acini Fig.(5A), in contrast, there is marked collagen fibers deposition around the thyroid acini in the connective tissue septa in AMD treated group, Fig. (5B). While, combined administration of AMD with α-LA in group III and AMD withdrawal in group IV showed only little collagen fibers deposition the connective tissue septa around thyroid acini Figs. (5C&D).

c. Immunohistochemical staining with ki67:

Control group, sections showed Ki67-negative immunohistochemical staining of the follicular cells lining the thyroid follicles and septal cells. Figure (6A), on the other hand, marked strong (dark brown) ki67 expressions were detected in AMD treated group (Fig. 6B). While obvious reduction of ki67 expression with mild Ki67-positive immune-staining of the follicular cells lining the thyroid follicles and septal cells is seen in co administration of AMD with α-LA group and AMD withdrawal group, more or less to normal level. (Figs. 6C&D).

2-Transmission electron microscopy (TEM) Findings:

In the control group, ultrastructure finding of the thyroid gland using TEM showed that the follicular cells showed that the apical border the microvilli (MV) protruding to colloidal lumen and contained rounded, regular euchromatic nuclei with regular and well-formed nuclear membrane, normal rough endoplasmic reticulum, Golgi, intact lysosomes and scattered mitochondria. Parafollicular cells revealed euchromatic large nuclei with regular and well-formed nuclear membrane, electron dense granules, normal organoids such as rough endoplasmic reticulae and mitochondria (Figs. 7A-D).

Contrary, TEM examination of thyroid gland of AMD administrated group showed follicular cell cytoplasm disorganization, The nucleus appeared large, irregular and heterochromatic (dispersed chromatin), with ill-defined nuclear membrane markedly dilated rough endoplasmic reticulae (rER), dilated cisternae of Golgi apparatus with secretory contents, markedly distended with glycogen, elongated, vacuolated, deformed pattern or degenerated mitochondria, abundant large inclusion lysosomes and deformed secondary lysosomes. Near the lumen or attached to rough endoplasmic reticulum, abundant secretory granules were found. Areas of absence of cytoplasm or fragmented cytoplasmic vesicles of degenerated cells were noticed. Moreover, Parafollicular cells showed disturbed cell membrane, areas of lost cytoplasm and degenerated mitochondria (Figs. 8, A-D).

However, thyroid follicles in either (AMD+ α-LA) group or (AMD withdrawal) group revealed marked improvement, with a preserved normal appearance of follicular and parafollicular cellular membranes and organoids. The nuclei seem euchromatic with a well-formed and regular nuclear membrane (Figs. 9A&B and 10A &B respectively).

3- Morphometric results:

In tables (2&3) and histograms (1&2), the statistical analysis of mean area percent of collagen fibers deposition and Ki67 immunopositive expression showed a significant elevation in AMD group when compared to control group, (AMD+ α-LA) group and (AMD withdrawal) group. Additionally, there was a significant elevation in (AMD withdrawal) group when compared to control group. In contrast, AMD+ α-LA group and AMD withdrawal group showed a significant reduction in main area percent of collagen fibers deposition and Ki67 immuno-positive expression in both groups when compared with AMD group. However, this reduction was found to be non-significant when compared AMD+ α-LA group with AMD withdrawal group.

Table (1): Statistical comparison among the studied groups as regard serum T3, T4, TSH, IL6, MDA & CAT

Parameters groups	T3 (ng/ml) (mean ±SD)	T4 (ug/dL) (mean± SD)	TSH (ng/ml) (mean± SD)	IL6(pg/ml) (mean± SD)	MDA (Mean ± SD)	CAT Mean ± SD
Control	0.397 ^b ±0.02	6.878 ^b ±1.79	0.648 ^b ±0.06	14.16 ^b ±1.4	14.75 ^b ±1.49	60.17 ^b ±2.8
AMD	0.184± ^{acdef} 0.03	3.828 ^{acdef} ±0.37	1.054 ^{acdef} ±0.11	26.67 ^{acdef} ±3.82	40.33 ^{acdef} ±2.59	25.48 ^{acdef} ±3.11
AMD+α-LA	0.392 ^b ±0.04	6.68 ^b ±1.86	0.653 ^b ±0.11	15.59 ^b ±1.48	15.4 ^b ±2.52	61.27 ^b ±4.27
AMD withdrawal	0.395 ^b ±0.03	6.89 ^b ±1.44	0.657 ^b ±0.11	14.53 ^b ±1.72	15.35 ^b ±2.96	57.45 ^b ±4.62
ANOVA (F test)	101.8	8.5	38.9	66.09	262.1	206.1
P value	0.001*	0.001*	0.001*	0.001*	0.001*	0.001*

a→ Significant in comparison with control group. b→ Significant in comparison with AMD group. c→ Significant in comparison with AMD+ α-LA group. d→ Significant in comparison with AMD withdrawal group.

Table (2): showing mean values of area percent Mallory ± SD in the 4 groups.

Mean% ± SD	Group I	Group II	Group III	Group IV
Mallory %	3.9±3.2	27.29 ±2.1	4.9 ±0.97	9.67 ± 0.71
Significance ≤ 0.05	With groups II & IV	With groups I , III & IV	With group II	With groups I & II

Table (3): showing mean values of area percent KI67immunoreactivity± SD in the 4 groups

Mean% ± SD	Group I	Group II	Group III	Group IV
KI67 %	3.75± 0.77	22.6 ± 1.3	4.9 ±2.4	9.4 ± 1.4
Significance ≤ 0.05	With groups II& IV	With groups I, III & IV	With group II	With groups I & II

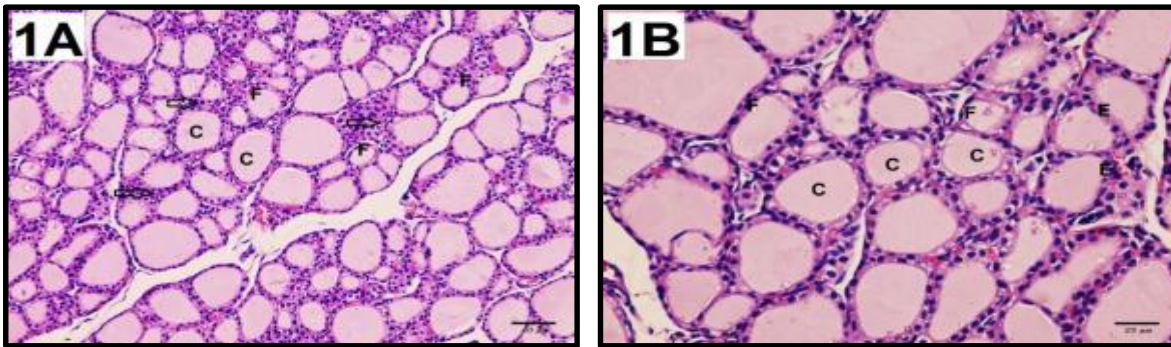


Figure (1): Photomicrographs of sections of control rats' thyroid gland tissues. -**(1A)**: showed follicles of different sizes (F) and lined by cuboidal follicular cells surrounding colloid (C) inside its lumen. Intermolecular cells appear normal in shape between the follicles (arrows) (H&E X200). **(1B)**: showed thyroid parenchyma with many thyroid follicles (F). The follicles are rich in colloid content and different in size (C) with cuboidal epithelial lining (E) (H&E X400).

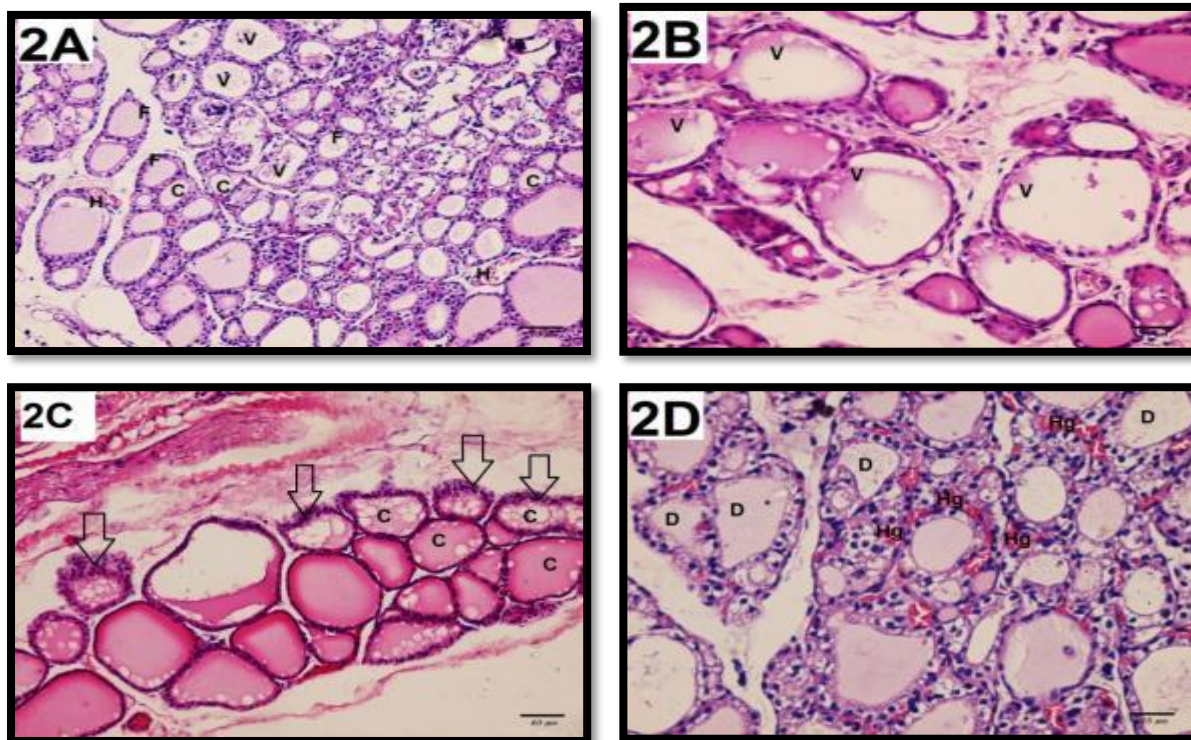


Figure (2): Photomicrographs of AMD treated rats' thyroid gland tissues sections. - **(2A)**: showed loss of normal architecture. The follicles showed irregular shape and size with many small follicles (F). Some of the follicles show vacuolations (V) with scanty amount of colloid (C) notice ruptured blood vessels between the follicles (H). (H & E X 200). - **(2B)**: The follicles became lined with abnormal epithelium with small amount of cytoplasm and vesicular nuclei. The colloid showed peripheral vacuolations (V) and some follicles are empty (H & E X 400). - **(2C)**: showed sever epithelial hyperplasia with abnormal nuclear features (arrows). They are lined by short columnar cells. Notice: Some follicles showed irregular amount of colloid (C). Fibrous tissue appears to be increased in the stroma between thyroid follicles. (H & E X 200). - **(2D)**: showed loss of its pattern with follicular damage (D) and hemorrhage (Hg) between the follicles. Interstitial tissues show areas of hemorrhage and necrosis with inflammatory cell ↑↑ infiltration (H&E X 400).

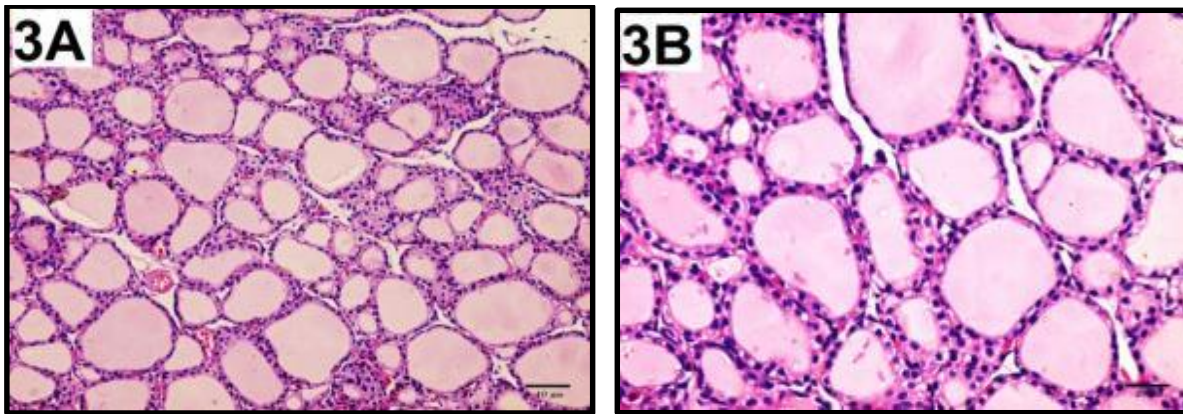


Figure (3): Photomicrographs of AMD co administered with α -LA rats' thyroid gland tissues sections. - **(3A):** showed that the thyroid gland tissues with its follicles regain the look of normal parenchyma. Good amount of colloids with normal cuboidal epithelial lining with very small amount of hemorrhage between the follicles in the majority of the follicles (H& E X 200). - **(3B):** showed the thyroid follicles with small amount of vacuolations with much less inflammatory infiltration without hyperplasia. Cuboidal epithelial lining covers most of the follicles which contain good amount of colloid (H&E X 400).

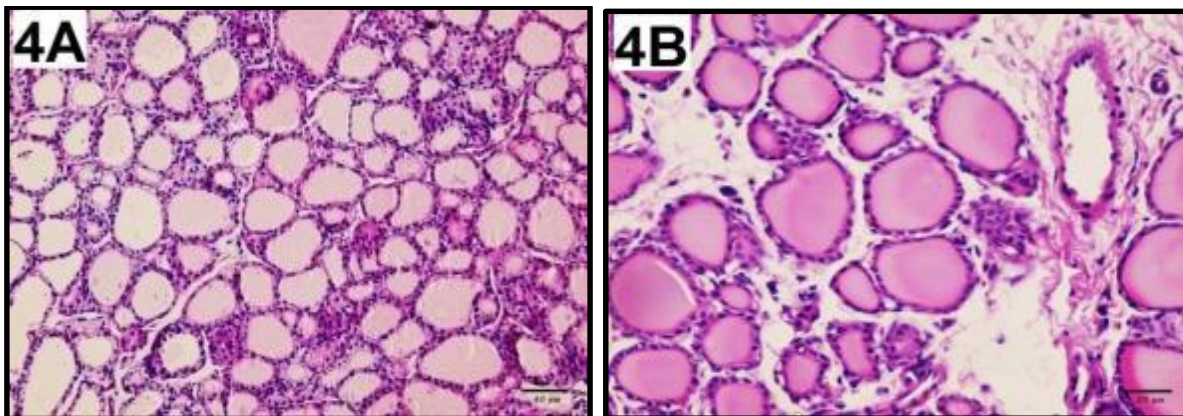


Figure (4): Photomicrographs of AMD withdrawal group thyroid gland sections - **(4A):** showed the thyroid tissues which nearly regained their normal parenchyma. The majority of follicles contain normal amount of colloids with normal cuboidal epithelial lining with very small amount of hemorrhage between the follicles (H& E X200). - **(4B):** showed the thyroid follicles with very little inflammatory infiltration and no hyperplasia. Most of the follicles are lined with cuboidal epithelial and contain a good amount of colloid (H& E X400).

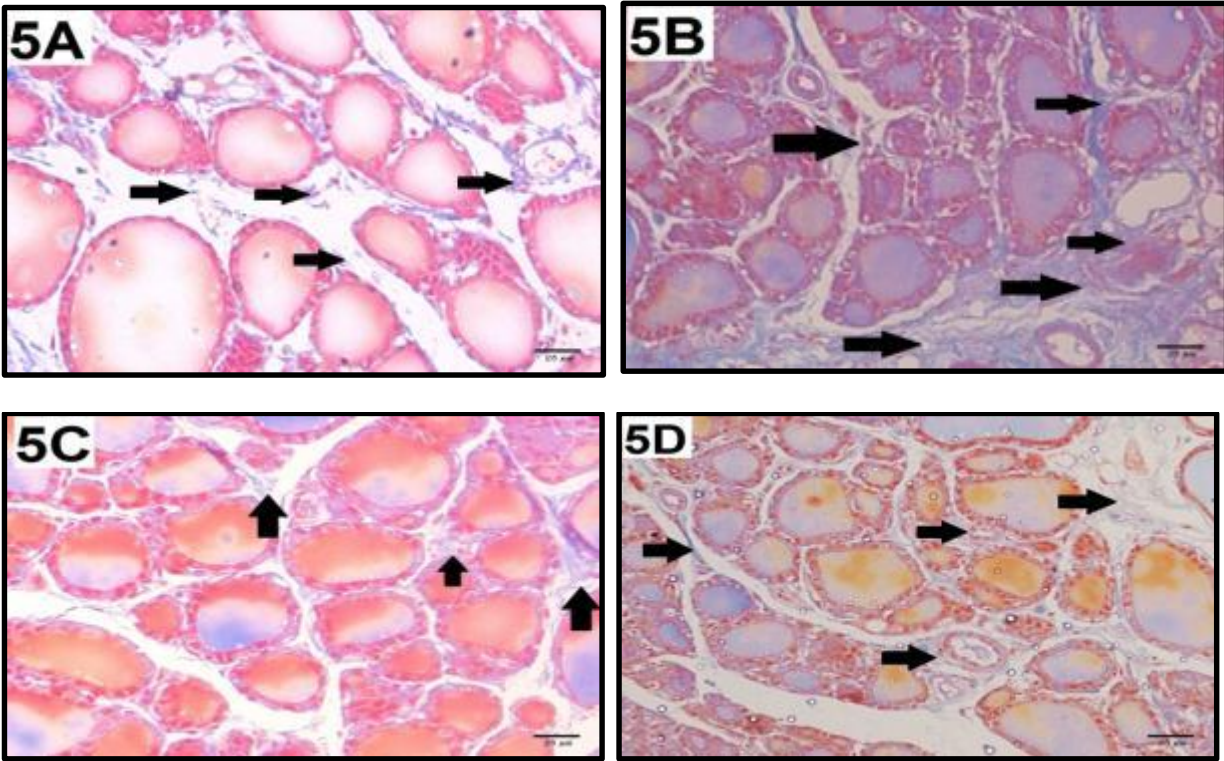


Figure (5): Photomicrographs of thyroid gland tissues sections. - (5A): showed little collagen fibers (arrows) around the thyroid acini in control group. - (5B): showed marked collagen fibers deposition (arrows) around the thyroid acini in AMD treated group. -(5C & D): Sections in AMD + α -LA group and AMD withdrawal group respectively, showed little collagen fibers deposition (arrows) around the thyroid acini. (Mallory's trichrome stain X400).

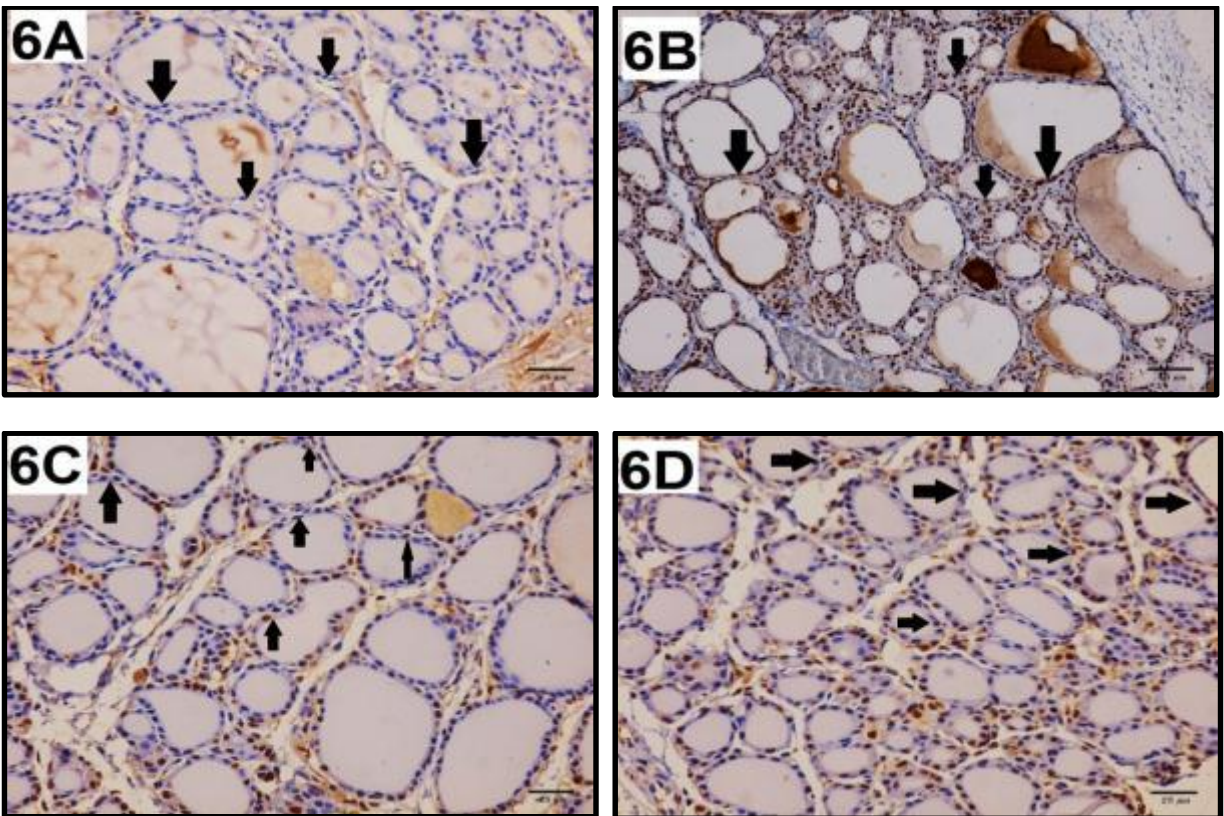


Figure (6): Photomicrographs of thyroid gland tissues sections. - (6A): a section in the control group showed Ki67-negative immunostaining of the follicular cells (black arrow) lining the thyroid follicles and septal cells. - (6B): a section in AMD treated group showed Ki67-strong positive immunostaining of the follicular cells (black arrow) lining the thyroid follicles and septal cell. -(6C & D): a section in the rat thyroid gland tissues of the AMD + α -LA group and in AMD withdrawal group respectively showed mild Ki67-positive immunostaining of the follicular cells (black arrow) lining the thyroid follicles and septal cells. (Ki67 immuno-stain X400).

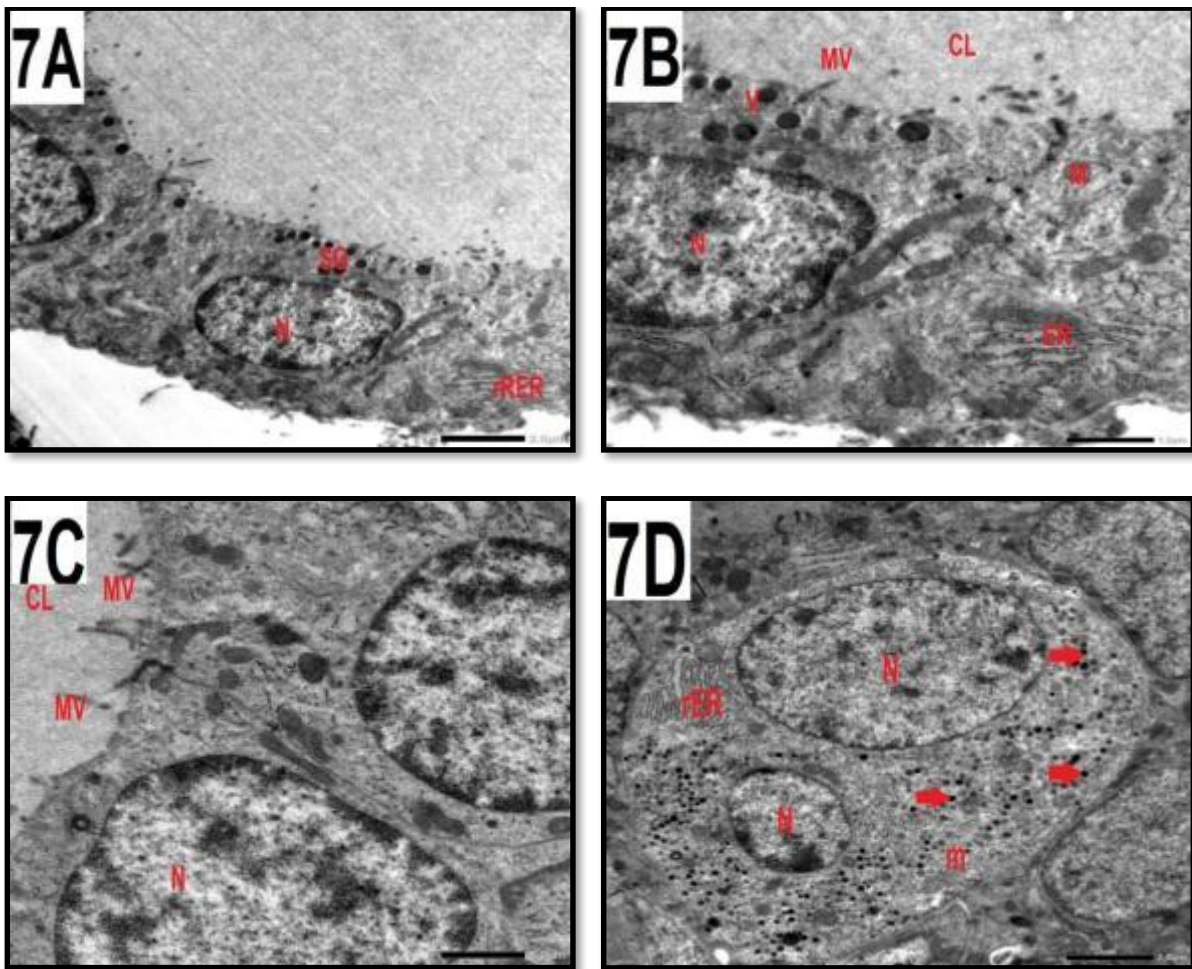


Figure (7): Electron photomicrographs of control rats' thyroid follicular cells - **(7A):** showed normal shape nucleus of follicular cell (N), apical secretory granules (SG), rough endoplasmic reticulum (rER), and scattered mitochondria (m) (TM X2500). - **(7B):** showed the thyroid follicular cells by a higher magnification for the previous figure. The cell has microvilli (MV) protruding into the colloidal lumen (CL) at its apical border. Mitochondria (M), small apical vesicles (V), both cisternal and vesicular forms of rough endoplasmic reticulum (rER) were found. The cells' base is formed by the subepithelial basal membrane (BM). The nucleus (N) has a regular and well-formed nuclear membrane and seems to be euchromatic. Near the base, blood vessels (BV) and Parafollicular cells (P) are visible. (TM X 5000). - **(7C):** showed portions of 2 neighboring thyroid follicles. The apical edge of the follicular cells has microvilli (MV) extending into the colloidal lumen (Cl). The nuclei (N) seem euchromatic, with a well-formed and regular nuclear membrane. (TM X5000). - **(7D):** thyroid Para follicular cell showed two nuclei (N) with regular and well-formed nuclear membrane and appear euchromatic. Many secretory granules (arrows), rough endoplasmic reticulum (rER), and scattered mitochondria (m) were found (TM X2500).

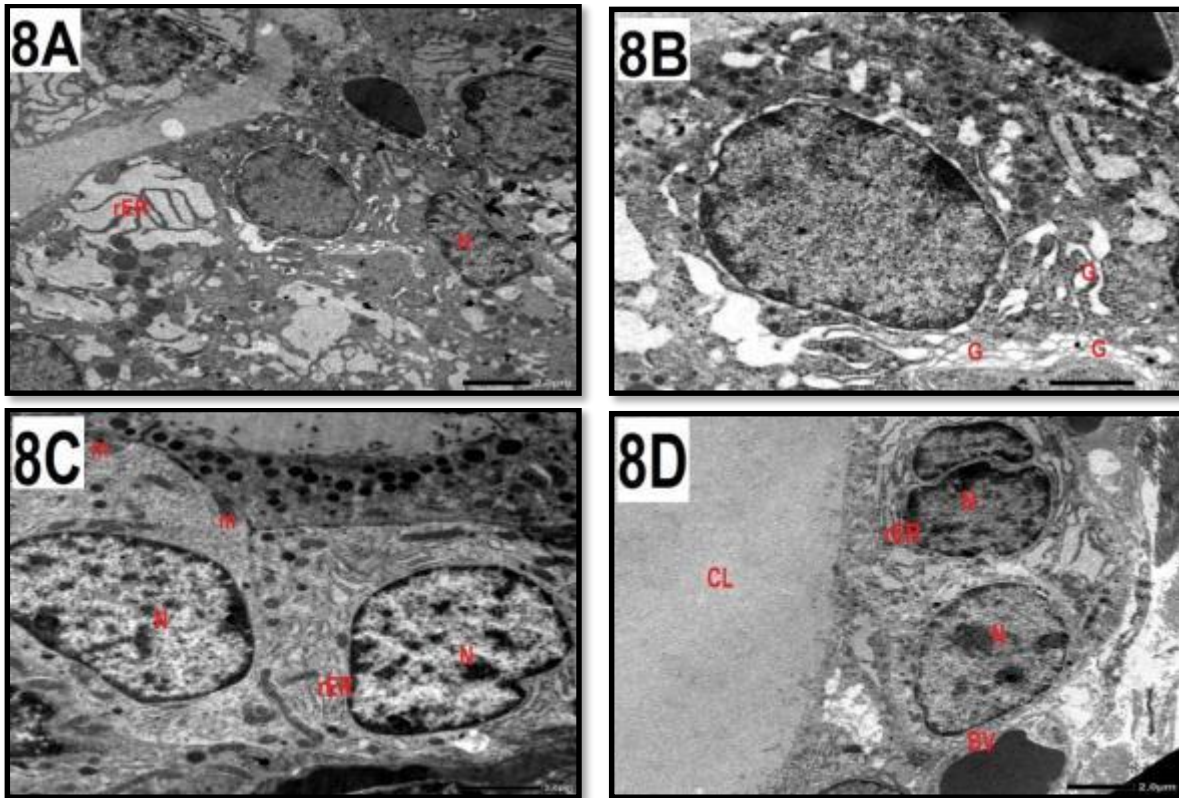


Figure (8): Electron micrographs of thyroid follicular cells of AMD treated group: -**(8A)**: showed dilated rER, many large lysosomes & irregular nucleus (N) (X2500). - **(8B)**: A bigger magnification of the previous follicular cell showed dilated cisterna of Golgi body (G) containing secretory material (TM X 5000). - **(8C)**: Showed the apical part of a thyroid follicular cell with abundant lysosomes with irregular nucleus (N) with dispersed chromatin, distended mitochondria (M) and marked dilated rER (TM X 2500). - **(8D)**: Showed heterochromatic nucleus (N) of a follicular cell, the cell has a substantial decrease in height, a poorly defined basal lamina that separates it from the blood vessel (BV), colloid droplets in the basal and apical regions of the cytoplasm, and the presence of massive colloid masses, along with an overall disorganization of the cytoplasm. Into the colloidal lumen (CL), a pseudopod emerges and protrudes. The nucleus is heterochromatic with a poorly defined nuclear membrane, and the other nucleus exhibits aberrant division and a significantly dilated rER. (TM X2500).

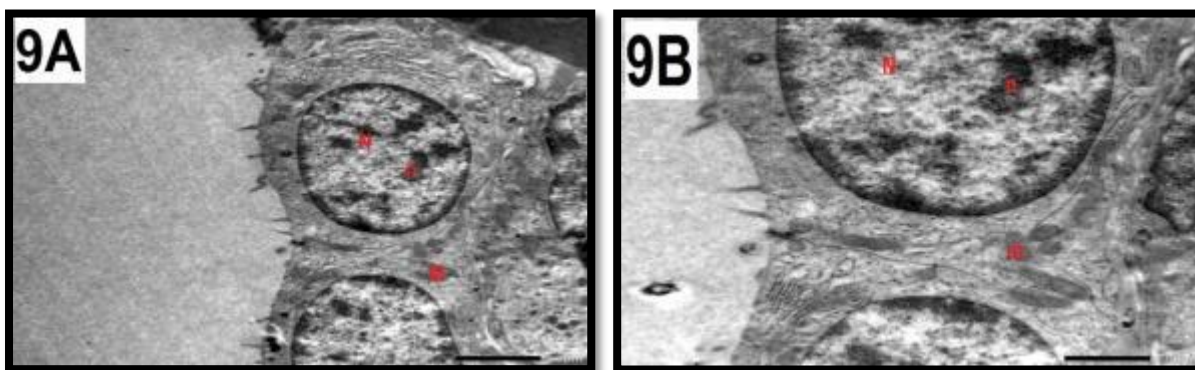


Figure (9): Electron photomicrographs of the thyroid gland of (AMD + α -LA) group. - **(9A)**: showed a follicular cell with an intact basement membrane (BM), Droplets of colloid and mitochondria (M) appear in the cytoplasm. The nucleus (N) is regular and euchromatic, with one or more nucleoli (n) and a well-formed nuclear membrane. (TM X2500). - **(9B)**: A further magnification of the preceding image, displaying colloid droplets, mitochondria (M), rough endoplasmic (rER), and tiny apical vesicles. The nuclei (N) are spherical and have pronounced nucleoli (n) (TM X5000).

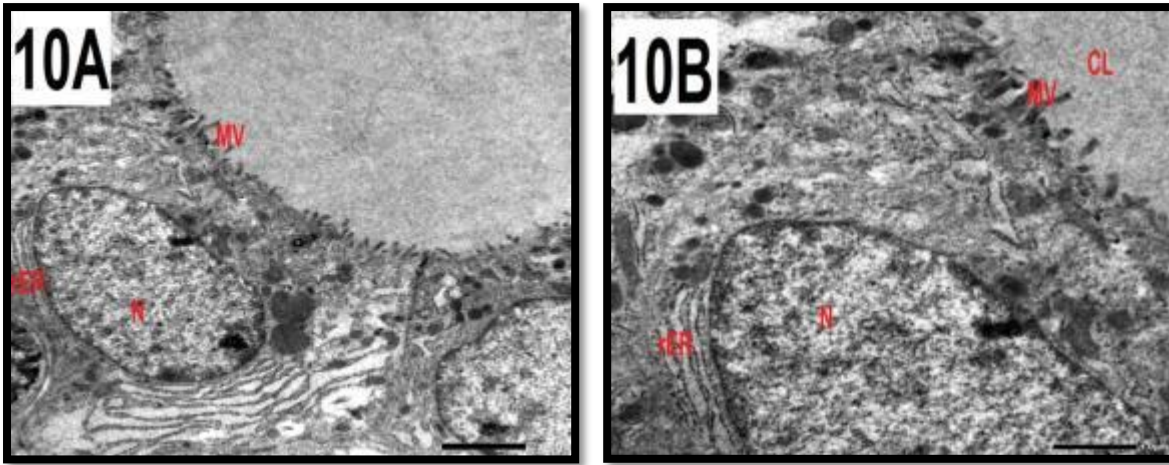
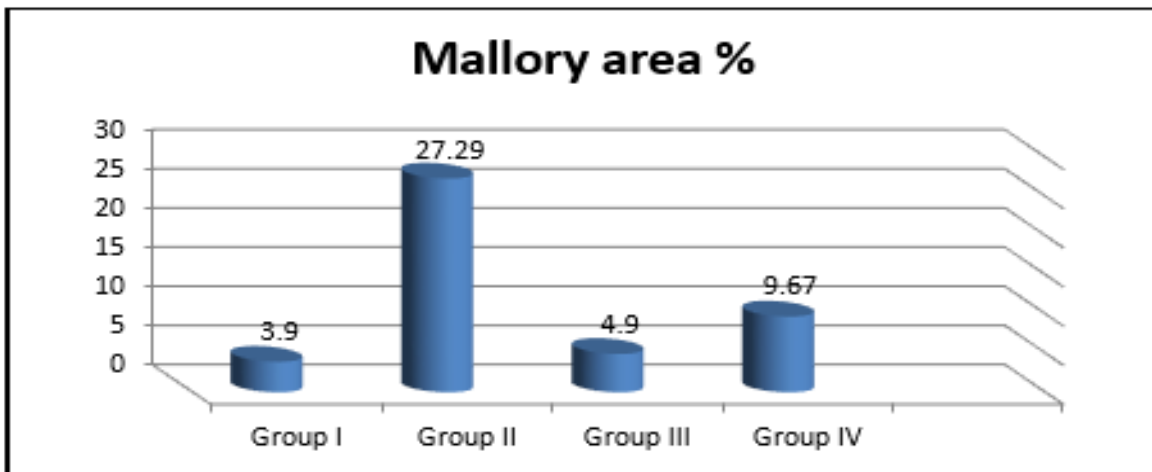
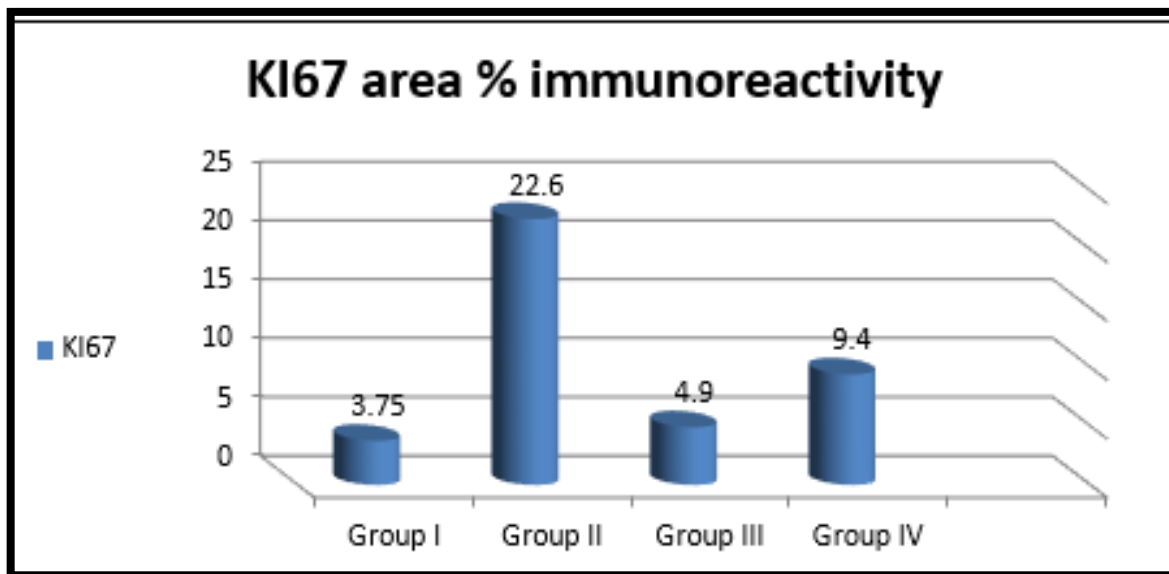


Figure (10): Electron photomicrographs of the thyroid gland of (AMD withdrawal) group: - **(10A):** Numerous apical microvilli (MV) extend into the colloid, normal-shaped Golgi apparatus and rER found in the follicular cells. The nuclei (N) are euchromatic with a regular, well-formed nuclear membrane and secretory granules of varying sizes (TM X2500). - **(10B):** A further magnification of the preceding image reveals the apical boundary with many microvilli (MV) extending into the colloidal lumen (CL). The nuclei (N) seem euchromatic with a regular, well-formed nuclear membrane and mitochondria of varying sizes (TM X5000).



Histogram (1): Bar chart showing the statistical analysis of the mean values of area percent of Mallory in the different studied groups



Histogram (2): Bar chart showing mean values of area percent of KI67 Immunoreactivity in the different studied groups

DISCUSSION

Amiodarone is a popular medication used in clinical applications for cardiac dysrhythmias management. Accumulation of AMD in the thyroid gland might result in gland dysfunction, either hypothyroidism or thyrotoxicosis⁽²⁰⁾.

Amiodarone has been widely identified to stimulate thyroid dysfunction through the mechanisms of direct effects of the drug, autoimmune effects, accumulation of oxidative free radicals, high iodine intake, or a combination of these mechanisms; also, its use frequently results in direct follicular cell damage and metabolic disorders of thyroid hormone synthesis^(21,22).

Amiodaron induced hypothyroidism (AIH) can happen in thyroid with underlying abnormalities or in normal thyroid glands Martino *et al.*⁽²³⁾, and the thyroid gland damage by preexisting Hashimoto's thyroiditis is the most likely pathogenic pathway in these conditions, which fail to escape from the acute effect of Wolff-Chaikoff after an iodine load and to restart normal synthesis of thyroid hormone. Subtle abnormalities in organification of iodine and thyroid hormone production are the best explanation for the onset of AIH in those without underlying thyroid diseases and negative thyroid autoantibody tests⁽²⁴⁾.

Consequently, about the hormonal assay results, the present study revealed hypothyroidism state as elucidated by marked decrease in the T3 and T4 levels, along with marked rise in TSH. These findings confirmed occurrence of hypothyroidism with chronic Amiodarone administration and were in accordance with Burger *et al.*⁽²⁵⁾ who investigated the Amiodarone impacts on the thyroid hormones peripheral metabolism leading to low T3 syndrome in chronically AMD treated individuals. In addition, Martino *et al.*⁽²³⁾ identified Amiodaron induced hypothyroidism (AIH) in chronically AMD treated individuals. Also, in the Batcher *et al.*⁽²⁶⁾ safe-trial, 30.8% of individuals receiving AMD experienced hypothyroidism. Martino *et al.*⁽²³⁾ and Ursella *et al.*⁽²⁴⁾ found that the development of Amiodaron induced hypothyroidism (AIH) is early, often happening within 6 months of initiating AMD treatment, and more commonly occurs than Amiodaron induced thyrotoxicosis (AIT) in iodine-sufficient regions.

In addition, Trip *et al.*⁽²⁷⁾ reported the most prevalent risk factor for Amiodaron induced hypothyroidism (AIH) development and persistence is Hashimoto's thyroiditis and is likely the reason of the female preponderance (male to female ratio 1: 1.5) and AIH is more common in iodine-sufficient communities. Martino *et al.*⁽²¹⁾ and Narayana *et al.*⁽²⁸⁾ found that AMD may hasten the natural course of Hashimoto's thyroiditis in patients with iodine-induced thyroid cellular damage and signs of thyroid autoimmune disease; however, hypothyroidism is more likely to persist.

Also, earlier research conducted by Loh⁽⁹⁾ revealed that AMD may influence thyroid hormone levels by altering their metabolism, transport, & function. Within 7 - 10 days of the initiation of AMD therapy, many of these alterations occur. AMD reduces 5'-monodeiodination (T4, T3 production, as well as clearance). This reduces plasma T3 levels and raises T3 levels. Reduced pituitary T3 production most likely explains the associated rise in TSH levels.

IL-6 is produced rapidly and transiently in response to tissue damage and infections and contributes to host defence by stimulating immunological reactions and acute phase responses. Although its expression is regulated by transcriptional and posttranscriptional processes, IL-6's pathological impact on autoimmunity and chronic inflammation results from its continuous synthesis dysregulation Tanaka *et al.*⁽²⁹⁾. Also, Nakajima *et al.*⁽³⁰⁾ and Trifanescu *et al.*⁽³¹⁾ reported that AMD increases IL-6 synthesis and secretion from thyroid follicles, and that at higher concentrations of AMD (10-25 M), IL-6 was enhanced through the increased IL-6 mRNA expression. Electron microscopy revealed cytotoxic effects of AMD at the thyroid level, which contributed to additional rise in IL-6 levels. This study found a significant increase in IL6 levels in rats treated with Amiodarone.

These results were supported by with El Sayed *et al.*⁽⁸⁾ who documented that chronic amiodarone administration induced destructive thyroiditis and thyroid cell damage. In the same line, Bogazzi *et al.*⁽¹⁰⁾ recorded variations in the serum concentration of IL-6 concurrently with thyroid dysfunction, where elevated serum IL-6 levels have been found in patients with AMD therapy exhibited thyroidal destructive processes with subsequent release of intracellularly stored cytokine, which was associated with extremely high serum IL6 levels.

Reactive oxygen species (ROS) are molecules that are chemically reactive and contain oxygen. Its accumulation may result in severe damage to cellular structures. There are numerous publications on Reactive oxygen species (ROS) and oxidative stress generated by excessive iodine.⁽³²⁾ Amiodarone (AMD) shares structural similarities with thyroid hormone, its structural similarities to thyroid hormones containing 39% iodine by weight causes an increase in the creation of free radicals, reactive oxygen species (ROS) generation, and associated problems in organs that are susceptible to stress⁽³²⁾.

About the oxidative stress parameters, the current study revealed significant elevations in the lipid peroxidation biomarker; MDA along with significant depletion in antioxidant enzyme activity; CAT following chronic AMD administration as compared to the other groups. In line with Chakraborty *et al.*⁽³²⁾, chronic AMD exposure results in cellular oxidative

stress for AMD metabolism and deiodination, liberating excessive iodine into circulation, which forms free radicals and ROS, resulting in cellular damage in organs susceptible to stress.

The histopathological examination of our study also afforded the evidence of the development of hypothyroidism, AMD treated rats' showed, loss of normal pattern and degeneration of thyroid gland follicles. The follicles were irregular in shape with marked epithelial hyperplasia of the lining of some follicles. This was in accordance with **Nakazawa *et al.***⁽³³⁾, who demonstrated that the majority of thyroid follicles are involuted follicles, which are strikingly swollen and distended with colloid material, lack scalloping, and are lined by flattened follicular cells. In the cytoplasm of several follicular cells there were vacuoles and a yellow pigment (lipofuscin). There were few inflammatory cells and fibrosis foci identified among the follicles. Occasionally, macrophages with a granular, foamy, and/or vacuolated appearance collected to create a hemispheric protrusion within the follicles. This signified destructive transformations.

As regard TEM examination of thyroid gland of AMD administrated group, the follicular cell showed cytoplasm disorganization. The nucleus appeared large, irregular and heterochromatic (dispersed chromatin), with ill-defined nuclear membrane markedly dilated rER, dilated cisternae of Golgi apparatus with secretory contents, markedly distended with glycogen, elongated, vacuolated, deformed pattern or degenerated mitochondria, this is in line with **Nakazawa *et al.***⁽³³⁾ who reported the electron microscopic changes on the thyroid gland caused by AMD, were ultrastructurally, follicular cells had few cytoplasmic organelles, dilated rER, and no microvilli. In addition, the cytoplasm of the follicular cells contains a number of enormous residual bodies made of massive lipid droplets and electron-dense pigments in the cytoplasm of follicular cells.

In our study, histological, immunohistochemical and electron microscopic picture of synchronous uses of AMD+ α -LA showed reverted the thyroid architecture mostly to normal with retained normal follicular pattern and structure with normal cuboidal epithelial lining and acidophilic colloid, These results were in agreement with **Xiang *et al.***⁽³⁴⁾ who found that hypothyroid patients exist impaired endothelial function, and antioxidant alpha-lipoic acid can improve endothelial function, through decrease of oxygen-derived free radicals.

ALA is a naturally occurring, short-chain fatty acid that is necessary for the activity of mitochondrial enzymes. It has antioxidant qualities and plays a vital role in protecting cells and tissues against the corrosive effects of free radicals and ROS. It is a naturally occurring antioxidant that neutralizes free radicals by promoting the regeneration of the body's endogenous antioxidants. In addition, it appears to enhance functional capacity when consumed as a dietary supplement **Abdou and Abdel-Daim**⁽³⁵⁾.

Additionally, our study, exhibited noteworthy protective findings following (α -LA) therapy; there were significant amelioration in hormonal assay and in oxidative stress indices along with improvement in histological, immunohistochemical and electron microscopic picture of synchronous uses of (AMD+ α -LA) which showed reverted the thyroid architecture mostly to normal with retained normal follicular pattern and structure with normal cuboidal epithelial lining and acidophilic colloid. These results were in accordance with **Xiang *et al.***⁽³⁴⁾ who reported that hypothyroid patients had decreased endothelial function and that the antioxidant α -LA can improve endothelial function by reducing oxygen-derived free radicals.

CONCLUSION AND RECOMMENDATIONS

In conclusion, the present study detected functional and histopathological toxic damage effects of AMD chronic administration and confirmed the hopeful protective role of α -LA in these cases. So we recommended for the patients receiving AMD therapy to be evaluated carefully before and during treatment including examination of thyroid gland and thyroid ultrasound on initial evaluation with baseline serum T3, T4 and TSH concentrations should be done, we also recommended concomitant administration of α -LA in such patients.

Conflict of interest: The authors had no conflict of interest to be cleared.

Fund: Non.

REFERENCES

1. **Goldschlager N, Epstein A, Naccarelli G *et al.* (2007):** A practical guide for clinicians who treat patients with amiodarone. *Heart Rhythm*, 4(9): 1250-1259.
2. **Yamada T, Hashida K, Takarada M *et al.* (2011):** α -Lipoic acid (LA) enantiomers protect SH-SY5Y cells against glutathione depletion. *Neurochem. Int.*, 59(7): 1003-1009.
3. **Valdecantos M, Pérez P, Quintero P *et al.* (2010):** Vitamin C, resveratrol and lipoic acid actions on isolated rat liver mitochondria: all antioxidants but different. *Redox Rep.*, 15(5): 207-216.
4. **Bulmus F, Gürsu M, Muz M *et al.* (2013):** Protective effects of alpha-lipoic acid on oleic acid-induced acute lung injury in rats. *Balkan Med. J.*, 30(3): 309-314.
5. **Lin Y, Lai Y, and Chou T (2013):** The protective effect of alpha lipoic acid in lipopolysaccharide-induced acute lung injury is mediated by hemoxygenase 1. *J Evid Based Complement Alternat Med. Evidence-based Complementary and Alternative Medicine*, (5): 590363.
6. **Benjamens S, Dullaart R, Sluiter W *et al.* (2017):** The clinical value of regular thyroid function tests during amiodarone treatment. *Eur. J. Endocrinol.*, 177(1): 9-14.
7. **LiVolsi V and Baloch Z (2018):** The pathology of hyperthyroidism. *Front Endocrinol. (Lausanne)*, 3(9): 737.
8. **El Sayed O, Gawish S, Aweida G *et al.* (2007):** Histopathological and biochemical toxic effect of amiodarone on thyroid gland in albino rat. *The Egyptian Journal of Hospital Medicine*, 29(1): 463-474.

9. **Loh, K. (2000):** Amiodarone-induced thyroid disorders: a clinical review. *Postgrad. Med. J.*, 76(893): 133-140.
10. **Bogazzi F, Bartalena L and Martino E (2010):** Approach to the patient with amiodarone-induced thyrotoxicosis. *Clin. Endocrinol. Metab.*, 95(6): 2529-2535.
11. **Bilaska A and Wlodek L (2005):** Lipoic acid - the drug of the future? *Pharmacol. Rep.*, 57 (5): 570-577.
12. **Paget G, and Barnes J (1964):** Evaluation of drug activities and pharmaceuticals 1st Ed. Academic press. London, PP. 135 – 155.
13. **Abdel-Daim M, Ramadan R, Emad W et al. (2016):** Synergistic ameliorative effects of sesame oil and alpha-lipoic acid against subacute diazinon toxicity in rats: hematological, biochemical, and antioxidant studies. *Can. J. Physiol. Pharmacol.*, 94(1): 81-88.
14. **Bancroft J and Layton C (2019):** The hematoxylin and eosin. In: Bancroft's theory and practice of histological techniques, (ELSEVIER, China). By: Suvarna, S.K., Layton, C. and Bancroft J.D. (eds.), 8th ed., Chapter (10), PP.126-183.
15. **Bancroft J and Layton C (2013):** The Hematoxylin and Eosin & Connective and mesenchymal tissues with their stains, In: Bancroft's theory and practice of histological techniques, Churchill Livingstone, London. By: Suvarna, S.K., Layton, C. and Bancroft J.D. (eds.), 8th ed., Chapter (10 & 11 respectively), PP: 172- 214.
16. **Hayat M (2000):** Principles and techniques of electron microscopy: biological applications. 4th ed., Cambridge: Cambridge University Press, pp:543.
17. **Takkem A, Barakat C, Zakaraia S et al. (2018):** Ki-67 prognostic value in different histological grades of oral epithelial dysplasia and oral squamous cell carcinoma. *Asian Pacific Journal of Cancer Prevention*, 19(11): 3279-3286.
18. **Dalvinder S, Nagar M and Prakash R (2015):** Histomorphometry of the Thyroid Gland in Rat after Lithium Administration. *Asian J. Pharm. Clin. Res.*, 8 (1): 339- 341.
19. **Sauro J and Lewis J (2016):** Quantifying the user experience: Practical statistics for user research. 2nd ed. Morgan Kaufmann (ed.), PP: 350.
20. **Martino E, Bartalena L, Bogazzi F et al. (2001):** The effects of amiodarone on the thyroid. *Endocr. Rev.*, 22(2): 240-254.
21. **Santangeli P, Di Biase L, Burkhardt J et al. (2012):** Examining the safety of amiodarone. *Expert. Opin. Drug Saf.*, 11: 191-214.
22. **Jiang L, Chen S, Xu J et al. (2016):** Dronedarone and Amiodarone Induce Dyslipidemia and Thyroid Dysfunction in Rats. *Cell Physiol. Biochem.*, 38: 2311-2322.
23. **Martino E, Aghini-Lombardi F, Mariotti S et al. (1987):** Amiodarone iodine- induced hypothyroidism: risk factors and follow-up in 28 cases. *Clin. Endocrinol.*, 26(2): 227-237.
24. **Ursella S, Testa A, Mazzone M et al. (2005):** Amiodarone-induced thyroid dysfunction in clinical practice. *Eur. Rev. Med. Pharmacol. Sci.*, 10(5): 269-78.
25. **Burger A, Dinichert D, Nicod P et al. (1976):** Effect of amiodarone on serum T3, T4 and TSH. A drug influencing peripherals metabolism of thyroid hormones. *J. Clin. invest.*, 58: 255 – 259.
26. **Batcher E, Tang X, Singh B et al. (2007):** Thyroid Function Abnormalities during Amiodarone Therapy for Persistent Atrial Fibrillation. *Am. J. Med.*, 120(10): 880-885.
27. **Trip M, Wiersinga W and Plomp T (1991):** Incidence, predictability, and pathogenesis of amiodarone-induced thyrotoxicosis and hypothyroidism. *Am. J. Med.*, 91(5): 507-511.
28. **Narayana S, Woods D, and Boos C (2011):** Management of amiodarone-related thyroid problems. *Ther. Adv. Endocrinol. Metab.*, 2(3): 115-126.
29. **Tanaka T, Narazaki M and Kishimoto T (2014) :** IL-6 in Inflammation, Immunity, and Disease. *Cold Spring Harb. Perspect. Biol.*, 6(10): a016295.
30. **Nakajima K, Yamazaki K, Yamada E et al. (2001):** Amiodarone stimulates interleukin-6 production in cultured human thyrocytes, exerting cytotoxic effects on thyroid follicles in suspension culture. *Thyroid*, 11(2): 101-109.
31. **Trifanescu R, Fica S, Dimulescu D et al. (2007):** Thyroid hormones and proinflammatory cytokines profile in amiodaron induced thyrotoxicosis... *Acta Endocrinologica (Buc)*, III (4): 417-436.
32. **Chakraborty A, Mondal C, Sinha S et al. (2014):** Amiodarone induced oxidative stress In stress - vulnerable organs of adult male rats. *Asian J. Pharm. Clin. Res.*, 7(4): 177-183.
33. **Nakazawa T, Murata S, Kondo T et al. (2008):** Histopathology of the thyroid in amiodarone-induced hypothyroidism, *Pathology International*, 58: 55-58.
34. **Xiang G, Sun H, Zhao L et al. (2010):** Alpha-lipoic acid improves endothelial dysfunction in patients with subclinical hypothyroidism. *Exp. Clin. Endocrinol. Diabetes*, 118(9): 625-629.
35. **Abdou R and Abdel-Daim M (2014):** Alpha-lipoic acid improves acute deltamethrin induced toxicity in rats. *Can. J. Physiol. Pharmacol.*, 92(9): 773-779.